HAL open science

Mobile-based deep learning system for early detection of diabetic retinopathy

El-Mehdi Chakour, Zineb Sadok, Rostom Kachouri, Anass Mansouri, Idriss Benatiya Andaloussi, Mohamed Akil, Ali Ahaitouf

To cite this version:

El-Mehdi Chakour, Zineb Sadok, Rostom Kachouri, Anass Mansouri, Idriss Benatiya Andaloussi, et al.. Mobile-based deep learning system for early detection of diabetic retinopathy. Intelligence-Based Medicine, 2025, 12, pp.100259. ⟨10.1016/j.ibmed.2025.100259⟩. ⟨hal-05269786⟩

HAL Id: hal-05269786

https://hal.u-pec.fr/hal-05269786v1

Submitted on 19 Sep 2025

HAL is a multi-disciplinary open access archive for the deposit and dissemination of scientific research documents, whether they are published or not. The documents may come from teaching and research institutions in France or abroad, or from public or private research centers.

L'archive ouverte pluridisciplinaire **HAL**, est destinée au dépôt et à la diffusion de documents scientifiques de niveau recherche, publiés ou non, émanant des établissements d'enseignement et de recherche français ou étrangers, des laboratoires publics ou privés.

Autorisation HAL

HAL Authorization

Mobile-Based Deep Learning System for Early Detection of Diabetic Retinopathy

El-Mehdi Chakour[a], Zineb Sadok[a,b], Rostom Kachouri[b], Anass Mansouri[c], Idriss Benatiya Andaloussi[c], Mohamed Akil[b], Ali Ahaitouf[a]

[a] *Laboratory of Intelligent Systems, Geo-resources and Renewable Energies, Faculty of Sciences and Technology, Sidi Mohamed Ben Abdellah University, Fez, Morocco*

[b] *Gaspard Monge Computer Science Laboratory, ESIEE Paris Gustave Eiffel University F-77454 Marne-la-Vallée, Paris, France*

[c] *Laboratory of Intelligent Systems, Geo-resources and Renewable Energies, National School of Applied Sciences, Sidi Mohamed Ben Abdellah University, Fez, Morocco., Fez, Morocco*

[d] *Ophthalmology Department, Hassan II Hospital, Sidi Mohamed Ben Abdellah University, Fez, Morocco*

Abstract

Diabetic retinopathy (DR) is a major cause of vision loss worldwide, particularly in regions where access to eye care is limited. Early detection is crucial to prevent irreversible damage. In this study, we propose an Assisted Mobile Diagnostic (AMD) system, a portable, real-time, deep learning-based solution for detecting DR. In contrast to conventional AI-based systems that rely on high-performance computers and tabletop fundus cameras, our approach integrates an optimized deep learning model for mobile execution into a mobile system combining a non-mydriatic retinal camera and a mobile device. The captured retinal images are preprocessed using techniques, including blurring and contrast enhancement, before being analyzed by a fine-tuned DenseNet-121 model. A private dataset for retinal images and two large public datasets, APTOS (Asia Pacific Tele-Ophthalmology Society) and EyePACS (Eye Picture Archive Communication System), were used to train and evaluate different deep transfer learning models. Our approach with DenseNet-121 achieves an accuracy of 97.38% on APTOS, 90.90% on EyePACS, and 98.61% on the private dataset. The system ensures real-time inference on mobile equipment, with an average processing time of 162.52 ms, enabling effective screening for DR screening. The MAD system facilitates tele-ophthalmology applications, seamlessly integrating into a multi-platform framework for remote diagnosis. The deep learning-based application is considered part of a multi-platform framework for tele-ophthalmology, integrating both a digital tablet and a desktop application.

Keywords: Deep learning-based Mobile Application, earlier screening of Diabetic Retinopathy, real-time eye diagnosis, handheld fundus camera.

1. INTRODUCTION

Early detection of diabetic retinopathy (DR) is essential to prevent blindness but remains limited by a lack of accessible equipment, particularly in medically under-resourced areas. With the rise of diabetes, which affected 463 million people in 2019 and could reach 700 million by 2025 [1], DR has become a major cause of visual impairment, with a particularly high prevalence in Africa (35.9%), the Middle East and North Africa (32.9%) and North America (33.3%)[2]. Fundus imaging plays a key role in the diagnosis of DR, enabling early signs to be identified before the emergence of irreversible complications. Portable retinal cameras represent an advanced alternative to traditional devices, offering a more accessible solution adapted to the constraints of mobile screening [3]. Their ability to capture high-quality images in real time, combined with their connectivity with tablets or smartphones, facilitates rapid data acquisition and analysis. This technology is particularly beneficial for rural areas where access to ophthalmologists is limited [4]. Moreover, the Ophthalmology Center and Vision Center at Omar Drissi Hospital, CHU HASSAN II, Fez, adopted these devices to improve access to early detection and reinforce the fight against the medical desert. Their portability enables healthcare professionals to carry out examinations in the field, facilitating access to care and improving patient care. Integrating an automated diagnostic assistance system would further strengthen this approach, facilitating the identification of high-risk cases and ensuring faster referral to specialists. By opening up access to screening, these new technologies significantly contribute to preventing eye disease and improving the visual health of the population at risk [5].

Therefore, the screening needs to be accessible, calling for an automated system Mobile-Aided Diagnosis (MAD), which is mobile, low-cost, and easy to use by an oculist, orthoptist, or nurse. Such a system must ensure the acquisition of patient fundus images in" real-time" using portable retinal cameras (non-mydriatic fundus cameras) connected either to desktops or digital tablets or smartphones, which will provide the screening results, thereby assisting in early diagnosis of DR, especially by detecting the earliest stage (i.e. the Mild no proliferative DR). Once the diagnosis results are established during the consultation, a deep examination by ophthalmologists occurs at a remote ophthalmology site [7].

The research presented in this article is part of a project that aims to design and develop an automatic system to assist in detecting and diagnosing ocular pathologies, using fundus images of the eye captured by portable retinal cameras. However, lesions that can be detected on fundus imaging are caused by the early stages of DR. These lesions appear at an early stage and include microaneurysms, hemorrhages, soft exudates, and hard exudates. Microaneurysms are the earliest signs resulting from the retinal capillaries' weakness. Hemorrhages result from the rupture of microaneurysms, while soft exudates are due to the leakage of lipids from damaged vessels. Hard exudates develop from lipid deposits and signify long-term retinal changes in the advanced stages of DR [6]. Early detection enables the provision of preventative treatment to stop DR progression, thereby reducing the risk of irreparable eye damage. The target system could be deployed on pilot sites as part of Tele-Ophthalmology networks. However, one such deployment is aimed towards the Fez region of Morocco, with a current diabetic patient count of 1.5 million, which is expected to increase to 2.6 million by 2030 [7].

Our targeted system developed as a Tele-Ophthalmology-based mobile application, will constitute a better approach to providing itinerant visual care in rural areas of Fez (Morocco) and its region (Rural Eye Care) as a first prototype, connected to a pilot site at the Tertiary Ophthalmology Center and Vision Center at Omar Drissi Hospital, CHU HASSAN II, Fez. This will eventually help overcome the serious dearth of ophthalmologists and contribute towards providing healthcare solutions at the patient's doorsteps. Currently, only 330 ophthalmologists work in the public sector, whereas more than 80% of the private sector's ophthalmologists are centered on the Casablanca-Kenitra axis [8]-[10]. Since, the images captured by portable retinal cameras may suffer from limitations such as blurriness, noise, or specific artifacts, which can complicate their interpretation by ophthalmologists and undermine the robustness of a real-time deep learning-based Assisted Mobile Diagnostic (AMD) system for detecting DR, the primary challenge of our approach lies in ensuring the highest possible quality of images acquired through mobile devices. In this context, this work makes the following contributions:

- A comparative analysis of noise reduction and contrast enhancement methods for fundus images from portable retinal cameras is performed, using image quality metrics like PSNR, SSIM, and RCEF for evaluation.
- The optimal preprocessing method is evaluated on two public datasets (APTOS, EyePACS) and then validated under real-world conditions on a private dataset wisch collected from CHU Hassan II Hospital (Fez), ensuring its robustness for the early detection of DR.
- A Mobile-aided diagnostic system is proposed for the early detection of DR, integrating optimized models (DenseNet-121, Inception-v3, MobileNetV2) and a tele-ophthalmology application to enhance diagnostic accuracy, accessibility to care, and the speed of medical intervention.

The rest of the paper is organized as follows. Section 2 provides a comprehensive review of existing research on early screening for DR using non-mydriatic handheld fundus cameras and the public datasets of retinal images. Section 3 focuses on our comparative study of fundus image-enhancing methods covering the datasets used. Section 4 describes the proposed method, which uses deep transfer learning models for early detection of DR, compares its performance with existing approaches, and details the implementation of a mobile application, showcasing its effectiveness for quick and accessible DR detection. Finally, we conclude in Section 5.

2. RELATED WORK

There are several levels of severity associated with the disease of DR. The main levels can be categorized as either non-proliferative (NPDR) or proliferative DR, the latter being the advanced stage. NPDR is further categorized into three stages: mild, moderate, and severe [4]-[11]. For DR detection, numerous computer-based techniques have been developed and reported in the literature. More recently, researchers have started using Deep Learning (DL) techniques for DR detection, particularly the transfer learning (TL) approaches, which have demonstrated promising results for image processing tasks [12]. Many computer-aided diagnosis methods for early screening and binary grading of DR

have been developed. For example, in [13], the authors have implemented a CNN (Convolutional Neural Network) using standard trainable and non-linear layers for DR detection. Wang et al [14] explored the use of deep transfer learning models such as AlexNet, VGG-16, and InceptionNetV3 for the diagnosis of DR. Their work demonstrated low accuracy results on retinal images from the Kaggle dataset, with accuracy rates of up to 37.43% for AlexNet, 50.03% for VGG-16 and 63.23% for InceptionNetV3. Pamadi et al. [15] worked using the MobileNetV2 architecture for binary and multimodal classification of DR images, with an accuracy of 78% on the Kaggle APTOS dataset in binary DR detection. Zhou et al. [16] presented a multi-cell architecture designed to increase learning speed and classification accuracy, achieving an accuracy rate of 63.22% for the diagnosis of DR. Deepa et al [17] presented an ensemble system comprising several deep-learning models to identify and classify DR. The model obtained a classification accuracy of 96.2% with 5-fold cross-validation. Imran Qureshi et al [18] proposed an active deep learning (ADL) method to identify and categorize the two states of diabetic retinopathy, "DR" and "No DR". It demonstrated a sensitivity of 92.20%, a specificity of 95.10%, an F1-score of 93.1% and an accuracy of 98.1%. Moreover, transfer learning (TL) techniques offer great advantages in achieving high performance while reducing training time, memory requirements, and network design efforts. One of the contributions of this work [19] is an overview of DL algorithm applications to classification-based studies in DR detection using fundus imaging. Moreover, most of the research articles reviewed in [20] focus on the transfer learning DCNN models for DR detection and grading.

To achieve the challenging goal of early detection of DR, the use of portable retinal cameras has become essential to the development of Tele-Ophthalmology, improving the detection of DR [21]. Recently, the application of transfer learning with adaptive fine-tuning for DR detection and classification has developed as a key tool in Tele-Ophthalmology [22]. In a study by Medina et al. [23], the Optomed Aurora portable fundus camera outperformed the standard table-top fundus camera in terms of sensitivity and specificity for DR screening. In another work [24], three portable fundus cameras, iNview, Peek Retina, and Pictor Plus, are compared for their sensitivity and specificity in detecting ocular diseases like DR. These fundus cameras demonstrated good results and effectively detected DR when used for Tele-Ophthalmology retinal screening consultations. The approach proposed in [25] uses a handheld portable fundus camera - Pictor Plus, Volk Optical Inc., USA - and performs DR grading using a deep learning system, Pegasus (AI software, Visulytix Ltd., UK), which resulted in 89.4% and 94.3% detection rates, for RDR and PDR AUROC (Area Under the Receiver Operating Characteristic) curves, respectively. The study was part of the Mexican Advanced Imaging Laboratory for Ocular Research (MAILOR) cohort.

The work presented in this article aims to deploy a telemedicine network for early DR detection. Our ultimate objective is to design and develop a mobile system, including a tele-ophthalmology mobile app that employs Deep Learning models and portable retinal cameras for screening and early diagnosis of DR. We first start with a mobile app for effective early detection of DR, mainly binary detection of "DR" or "No DR" because of its ability to provide rapid and decisive results. This approach enables early and targeted medical intervention, improving patient outcomes by reducing diagnostic delays and facilitating rapid and appropriate treatment. In this context, we are collaborating with

the Ophthalmology Center and Vision Center at Omar Drissi Hospital, CHU HASSAN II, Fez [26] [27]. Other than DR, our proposed approach can be used and easily adapted to other eye diseases, as shown by our work on Glaucoma [28] and AMD (age-related macular degeneration) [29].

3. COMPARATIVE ANALYSIS OF FUNDUS IMAGE ENHANCEMENT TECHNIQUES

Retinal image fundus is highly susceptible to contrast issues, including noise and inhomogeneity, reducing contrast and saturation. These artifacts significantly degrade the quality of acquired images, especially when using handheld and portable fundus cameras. Consequently, preprocessing retinal images is crucial in detecting and classifying retinal diseases. By applying mathematical techniques, the initial image quality and information content can be enhanced, thereby improving the recognition of distinctive features and optimizing subsequent image analysis. The overall framework for enhancing retinal images is illustrated in Figure 1.

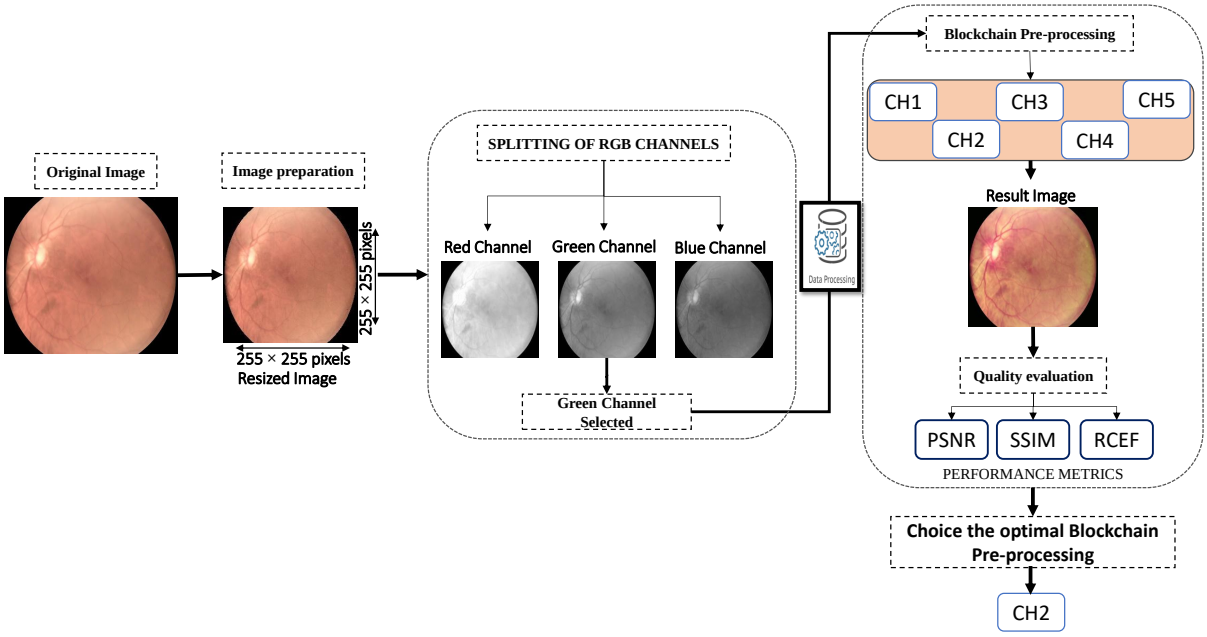

Figure 1: Flowchart of Enhancing Retinal Image Quality through Preprocessing Block Diagram.

The proposed preprocessing for enhancing retinal fundus images includes several steps. The retinal image is first captured and resized to optimize its dimensions, thereby reducing processing time. Next, the image is partitioned into distinct color components, namely red, green, and blue. Emphasizing the green channel assumes critical importance due to its ability to preserve intricate color details within the image [10]. Subsequent image enhancement is achieved through the application of various filters, including sequential combinations of smoothing and sharpening techniques, to further refine the enhanced image. Finally, the effectiveness of the entire process is evaluated using three metrics: the PSNR, the SSIM, and the RCEF. These metrics offer valuable insights into the final image quality and serve as a quantitative assessment of the performance at each stage of the process.

3.1. Private Dataset Description

3.1.1. Dataset Collection Process

In the field of DR research, several projects have recently focused on creating private databases using portable retinal cameras to better understand and analyze this condition. Collecting data at the local level through these portable technologies improves detection systems by adapting them to regional characteristics and demographic differences among patients [21][25]. Therefore, collecting private datasets is essential, as it provides more relevant data adapted to each context. Our collaboration with the Department of Ophthalmology at Omar Drissi Hospital (CHU Hassan II) in Fez, Morocco, emphasizes this approach by using a portable retinal camera, which allows for efficient data collection for more accurate and personalized DR detection.

The private dataset collected comprises retinal fundus images obtained using the oDocs Nun IR camera, a portable and non-mydriatic imaging device specifically designed for DR detection, as presented in Figure 2. To ensure representativeness and clinical relevance, images were collected from patients diagnosed with varying stages of DR, as confirmed through ophthalmological examinations. The dataset collection followed strict inclusion criteria, targeting patients aged 18 years and older with a confirmed history of diabetes. Additionally, patients with other retinal pathologies or ocular conditions were excluded to maintain the specificity of the dataset for DR analysis.

Figure 2: oDocs nun IR Retinal Camera [30].

The choice of the oDocs Nun IR retinal camera for image acquisition is based on several key advantages. It offers a high resolution of 2880×2160 pixels and a wide field of view (FOV) of 45° to 55°, allowing for precise visualization of retinal features. Its manual focus capability, ranging from -20D to +20D, ensures optimal image sharpness. The camera's portability and compatibility with Android smartphones make it ideal for use in remote areas with limited ophthalmological resources. The oDocs Nun IR captures critical details such as microaneurysms and hemorrhages, essential for accurate detection

and staging of diabetic retinopathy (DR). This device combines high performance with accessibility, particularly in hard-to-reach areas. Additionally, the proposed pipeline is compatible with other portable retinal cameras, providing flexibility for various clinical contexts and ensuring effective detection of DR across different environments.

3.1.2. Data Quality and Preprocessing

The private dataset used in this work consists of 1,319 retinal images, exhibiting a range of quality attributes. Figure 3 illustrates representative samples from the dataset. High-quality images (Fig 3.a) demonstrate precise details, minimal noise, and enhanced contrast, ensuring their suitability for analysis. Conversely, the dataset includes images with notable quality deficiencies, such as blur (Fig 3.b), noise (Fig 3.c), and insufficient contrast enhancement (Fig 3.d). To address these issues, additional image processing techniques, including deblurring and contrast enhancement, were applied to ensure that all images met the necessary standards for ophthalmological interpretation and deep learning analysis.

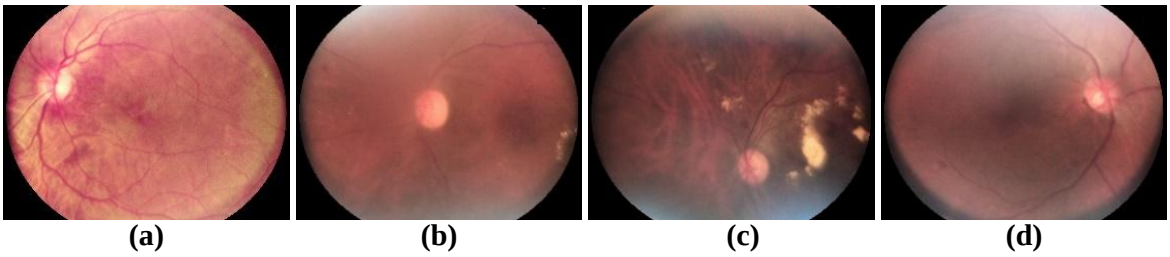

Figure 3: Example of Image Clarity (a), Blurriness (b), Contrast (c), and Brightness Variation (d) from the private dataset.

3.1.3. Dataset Annotation and Labeling

The data collection process strictly adhered to ethical guidelines to ensure patient confidentiality and compliance with international data protection standards. Ethical approval was obtained from an independent ethics committee, and all participants provided written informed consent before data collection. To safeguard patient data, robust security measures were implemented, including image and metadata anonymization, secure storage on encrypted servers, and restricted access limited to authorized personnel. These measures ensured that the dataset adhered to high standards of data privacy and security, following best practices in medical research.

The dataset was annotated by a team of three experienced ophthalmologists, who independently reviewed and classified first the images into five distinct stages of DR: absence of DR, non-proliferative diabetic retinopathy (NPDR) minimal, NPDR moderate, NPDR severe, and proliferative diabetic retinopathy (PDR). To ensure inter-rater reliability, classification disagreements were resolved through a consensus process, involving a fourth expert when necessary. The final labeled dataset is distributed as follows: 256 images with no DR, 381 images with minimal NPDR, 335 images with moderate NPDR, 253 images with severe NPDR, and 94 images with PDR. The labeling process adhered to internationally recognized DR classification guidelines, ensuring consistency, accuracy,

and reproducibility in the dataset. Moreover, the "No DR" stage was separated, while the four stages containing retinal lesions were merged into a single stage labeled "DR." This approach facilitates the identification of DR in its early stages while simplifying the classification of more advanced forms of the disease.

3.2. Public Datasets Description

In addition to the private dataset used in this study, two widely recognized public datasets, APTOS [32] and EyePACS [33], were also employed. The increasing demand for validation and training of deep learning models has driven research groups to create and release exclusive datasets to the public [31]. Among these, the APTOS and EyePACS datasets have gained significant recognition in the research community for their comprehensive collection of high-resolution retinal fundus images.

3.2.1. APTOS

The APTOS 2019 [32] Blindness Detection dataset proves to be a valuable resource for researchers and practitioners in the field of DR. This dataset encompasses a collection of fundus images effectively portraying the five distinct stages of DR. Each image is thoroughly labeled with a severity level, which spans the spectrum from 0 to 4. These severity levels correspond to specific categories: Label 0 signifies the absence of DR, label 1 indicates mild DR, label 2 represents moderate DR, label 3 denotes severe DR, and label 4 indicates proliferative DR. In total, the dataset consists of 3662 retinal images. Among these, 1805 images are meticulously classified as exhibiting no DR, 370 images are labeled as mild DR, 999 images are classified as moderate DR, 193 images are identified as severe DR, and 295 embody the characteristics of proliferative DR. The fundus image resolution within this dataset maintains a high standard at 3216×2136 pixels, ensuring a repository of visuals with remarkable quality, optimally suited for analysis and evaluation endeavors [34].

3.2.2. EyePACS

The EyePACS [33] dataset, similar to the APTOS dataset, provides an extensive compilation of fundus images capturing the complete spectrum of DR progression across its five stages. Comprising a total of 35126 retina images, with each image corresponding to both the left and right eyes. These images boast dimensions of 3888×2951 pixels, ensuring high-resolution visual data for analysis and research purposes. Within the EyePACS dataset, the images are meticulously categorized according to the five DR stages. Specifically, there are 25810 images labeled as having no DR, 2443 images classified as mild DR, 5292 images portraying moderate DR, 873 images indicating severe DR, and 708 images showcasing proliferative DR. For the training process of the proposed model, a random selection strategy is adopted, choosing 1534 images from the no DR stage and 2764 images from the DR stage.

3.3. Proposed flowchart and analysis of enhancement techniques

Image quality enhancement techniques aim to optimize images by reducing undesired disturbances, enhancing the visibility of important features, and improving overall picture quality. One effective approach for enhancing image quality involves accentuating the contrast between dark and light regions. This can be achieved through the application of

filters, which are commonly employed in low-quality image processing tasks. A variety of filters can be used to enhance the visual quality of images, including those that provide a softer appearance, enhance details, or emphasize edges. Previous research has explored the effectiveness of employing 11 simple filters to enhance the quality of retinal images [35]. These filters have demonstrated reliability in improving the clarity of blood vessels within the images. Before applying these filters, the images undergo initial preprocessing steps, such as resizing and selection of the "Green channel", which contains the most detailed color information. In our approach, we specifically employ 5 high-performance filters that have yielded favorable outcomes. These filters include the median filter (MF), the non-local means filter (NLMF), the Gaussian filter (GF), contrast-limited adaptive histogram equalization (CLAHE), and the bilateral filter (BF). Detailed descriptions of these filters, along with their respective mathematical formulas, are provided, and the resulting images they produce are visually illustrated in Table 1.

Within this context, the application of the median filter serves as a noise-reduction method that maintains edge preservation by substituting pixels with the median value derived from their neighboring pixels. This technique proves particularly advantageous for retinal images as it effectively eliminates extreme values induced by noise. Conversely, the Contrast-Limited Adaptive Histogram Equalization (CLAHE) filter enhances contrast by adaptively adjusting pixel values based on local regions. This approach is highly effective in accentuating crucial details such as blood vessels, although meticulous application is necessary to prevent the amplification of noise. Both filters play a significant role in enhancing the quality and analyzability of retinal images. In addition to the above-listed filters, we also implemented and evaluated the enhanced median filter (EMF), as well as the median filter combined with an average filter (MMF) [36]. It is noteworthy that the MMF performs poorly compared to the other five tested filters in terms of PSNR, SSIM, and RCEF [29], and these results are not presented here.

3.3.1. Enhancement chains

To construct preprocessing chains, the most successful filter outcomes are selected. These chains consist of multiple stages, including denoising, contrast enhancement, and the application of adaptive gamma correction. Among the filters that demonstrated notable effectiveness are those listed in Table 1. The MF, GF, BF, and NLMF work as smoothing filters, while CLAHE acts as a sharpening filter. As a result, a combination of both smoothing and sharpening filters is employed within the chains. Adaptive gamma correction (AGC) is a technique that adjusts the intensity values of pixels in an image based on a gamma correction curve (GCC) [37]. According to this formula, for an image of size m × n pixels, the gamma correction transforms the intensity value of the pixel at each spatial position (x, y) according to the following expression:

$$I_{\text{gam}}(x, y) = I(x, y)^{\gamma} \tag{1}$$

Where $I_{\text{gam}}(x, y)$ represents the gamma-corrected intensity of the image I (x, y), and γ represents different gamma values that control the type of mapping. When γ is set to a value $\gamma > 1$, the dark regions of the original image become brighter in the gamma-corrected intensity image. Conversely, when γ is set to a value $\gamma < 1$, the bright regions of the original image become darker in the gamma-corrected intensity image [38]. It is

Table 1: Filters with their mathematical expressions and output images.

Filters	Mathematical Expressions	Output Images
MF	$g(x,y) = \text{median}\{f(n,m)\}$ Where $f(n,m)$ returns the pixel value at position (n,m) in the image.	
GF	$G(x,y) = \frac{1}{2\pi\sigma^2} \mathrm{e}^{-\left(\mathrm{x}^2+\mathrm{y}^2\right)/2\sigma}$ Where G(x, y) is the value of the Gaussian filter at a given position (x, y). σ: the standard deviation of the Gaussian filter.	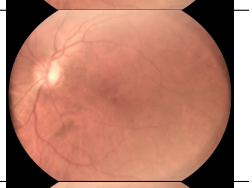
BF	$I = \frac{1}{W_P} \sum_{X_i} I\left(x_i\right) f_i\left(\left\lVert I\left(x_i\right) - I(x)\right\rVert\right)$ Where w_P is the normalization factor. $I(x)$ is the intensity of the pixel being processed. $\mathbf{x_i}$ are the neighboring pixels around the pixel being processed.	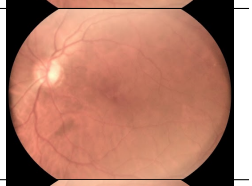
NLMF	$\text{NLMF(x)} = \left(\frac{1}{\text{Z(x)}}\right) * \sum(\text{w(x, y)} * \text{f(y)})$ Where Z(x) is a normalization factor. $\sum(\text{w(x, y)} * \text{f(y)})$ represents the weighted sum of similar pixel values f(y) based on their weights w(x, y).	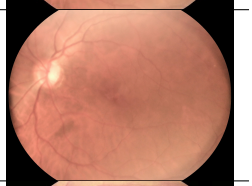
CLAHE	$g = [g_{\max} - g_{\min}] * p(f) + g_{\min}$ Where $g_{\max}$, $g_{\min}$ are the maximum and minimum grey levels. $p(f)$ is the cumulative probability of grey level f in a local region of the input image.	

important to note that the gamma value is adaptive for each image, which means that each image has its gamma value based on its intensity characteristics.

3.3.2. Performance metrics

The performance of the image processing algorithms or enhancement filters can be evaluated by various quantitative measures. The metrics such as PSNR, RCEF, and SSIM are used to find which image enhancement techniques give better results. PSNR is the most commonly used metric for image enhancement techniques and is given by:

$$PNSR = 10 \log_{10} \frac{255^2}{\frac{1}{MN} \sum_{ij} \left[g_{ij} - f_{ij}\right]^2} dB \tag{2}$$

Where f and g are the original and the enhanced images and M and N are the row and column pixels in the image, respectively. The subscripts i and j correspond respectively to the row and column indexes. The highest PSNR value gives better performance. The change in the structural similarity between the original and enhanced images is measured by the SSIM and is given by:

$$\text{SSIM}(A,B) = \frac{\left(2\mu_A\mu_B + c_1\right)\left(2\sigma_{AB} + c_2\right)}{\left(\mu_A^2 + \mu_B^2 + c_2\right)\left(\sigma_A^2 + \sigma_B^2 + c_2\right)} \tag{3}$$

Table 2: Performance Evaluation of Image Quality using PSNR, SSIM, and RCEF Metrics

	Blockchain	SSIM	PSNR	RCEF
chain **1**	MF+CLAHE+AGC	0,9804	33,2531	1,0177
chain 2	**GF+CLAHE+ AGC**	**0,9808**	**33,2950**	**1,0476**
chain 3	BF+CLAHE+ AGC	0,9803	33,2317	1,0378
chain 4	NLM+CLAHE+ AGC	0,9804	33,2096	1,0381
chain 5	MMF+CLAHE+ AGC	0,9802	33,2641	1,0276

Where μ_A and μ_B are the average of the intensities in the images x and y, respectively. These averages are calculated over a local neighborhood or window of pixels. ${\sigma_A}^2, {\sigma_B}^2$ and σ_{AB} are the variance and covariance of x and y, and c_1 and c_2 are constants added to the formula and chosen to avoid division by zero and ensure numerical stability. The SSIM values range from -1 to 1; if the value is exactly one, it is considered to be of a perfect structure similarity, and if the value is lower, then there is no structural similarity. The dynamic range of the histogram is measured using RCEF and is given by:

$$\text{RCEF} = \frac{\sigma_{\text{B}}^2/\mu_{\text{B}}}{\sigma_{\text{A}}^2/\mu_{\text{A}}} \tag{4}$$

Where σ_A and σ_B are the standard deviation of the original and enhanced image, and μ_{A} and μ_{B} are the mean of the pixel values in the original and enhanced images, respectively. The mean provides a measure of the central tendency or average intensity of the image. If RCEF is greater than 1, it suggests that the enhanced image has a higher contrast and a wider range of pixel values compared to the original image.

3.3.3. Image quality Evaluation

The five image enhancement chains, thus proposed, are separately evaluated, and the results are shown in Table 2. Significant findings regarding the different filter chains are highlighted. Among them, chain 2, which incorporates the GF+CLAHE+AGC filter combination, stands out as it demonstrates superior performance compared to the others. Chain 2 achieves a high SSIM value of 0.9808 and a PSNR value of 33.2950, indicating a closer structural similarity between the reference and improved image quality. Due to its superior performance, Chain 2 was selected for use in the subsequent stages of the detection and classification approach discussed in Section 4. This chain effectively enhances image quality, reduces noise, and improves contrast. These enhancements contribute to more accurate and reliable detection and classification of retinopathy cases, ensuring robust results across varying image conditions. Figure **4** showcases the outcomes of the best optimal preprocessing blockchain, yielding the respective output images for (a) and (b), denoted as (c) and (d) in the sequence. The processing chain involves the application of a Gaussian Filter followed by merging channels. The Gaussian Filter helps in reducing noise and smoothing the images, while the merging channels operation combines the different color channels to create the final enhanced output. This procedure aims to enhance the quality of retinal images, enabling improved analysis and interpretation for various applications.

The early screening for DR involves two distinct stages: non-proliferative DR (NPDR) and proliferative DR (PDR). NPDR represents the initial stage of the disease, character-

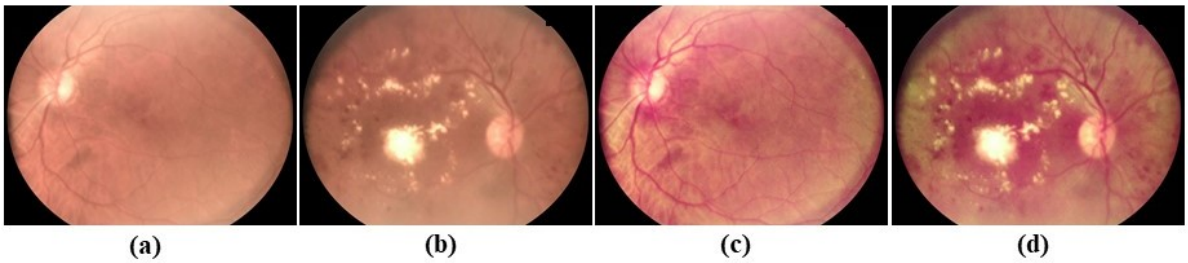

Figure 4: The best enhancement chain involves Gaussian Filter, CLAHE, and Gamma correction to improve retinal image quality (a) and (b) original images, (c) and (d) are the output results corresponding to (a) and (b) respectively.

ized by retinal lesions such as microaneurysms, hemorrhages, and exudates. On the other hand, PDR corresponds to the advanced stage, characterized by the formation of new abnormal blood vessels in the retina [40]. The acquired images enable the visualization of characteristic DR lesions and facilitate the determination of the disease stage [38]. In this study, a combination of the three non-proliferative diabetic retinopathy (NPDR) stages (minime, moderate, severe) and the PDR into a single class named "DR" is considered, while keeping the "No DR" class separate. Figure 5 shows the original images from the private dataset (a), APTOS (b), and EyePACS (c) respectively, and the corresponding results of the optimal preprocessing blocks (d), (e) and (f) used in this research.

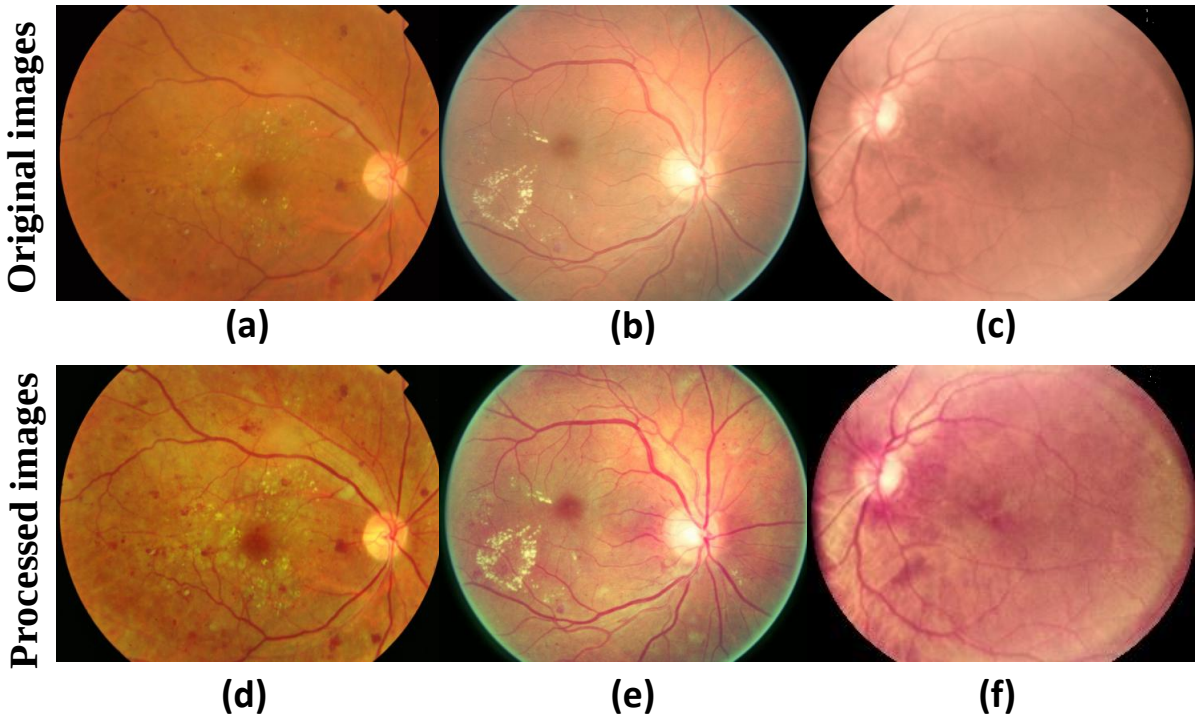

Figure 5: Preprocessed Retinal Fundus Images: (a) and (d) APTOS dataset, (b) and (e) EyePACS dataset, (c) and (f) private dataset.

4. PROPOSED METHOD

Image classification consists of assigning a specific class or label to a new, unseen image. This process leverages pre-trained models to predict class labels for unknown images based on a dataset of annotated examples. Deep neural networks (DNNs) are among the most widely used architectures for image classification due to their ability to automatically learn hierarchical features such as edges, textures, shapes, and their spatial relationships. These networks are highly proficient at detecting and encoding intricate patterns within data, making them particularly effective for tasks that require high accuracy in image recognition and classification. The method proposed in this study comprises three essential steps. First, data preparation is performed to prepare the model for the classification task. Second, data pre-processing is performed by selecting the best pre-processing chain identified in the study mentioned in section 3. In addition, data augmentation is applied to increase data diversity and improve model generalization, while the cross-validation 5-Fold technique is used to robustly evaluate model performance. However, three deep learning models, based on the transfer learning approach and fine-tuning of the DenseNet-121, Inception-v3, and MobileNet-v2 architectures, are employed. These pre-trained models are further refined to extract a wide range of lesion features from retinal images, enhancing the model's ability to identify and classify subtle patterns indicative of diabetic retinopathy. Finally, the early detection of diabetic retinopathy has been implemented into a mobile application designed to detect the presence of DR. The detailed flowchart of the proposed method is shown in Figure 6.

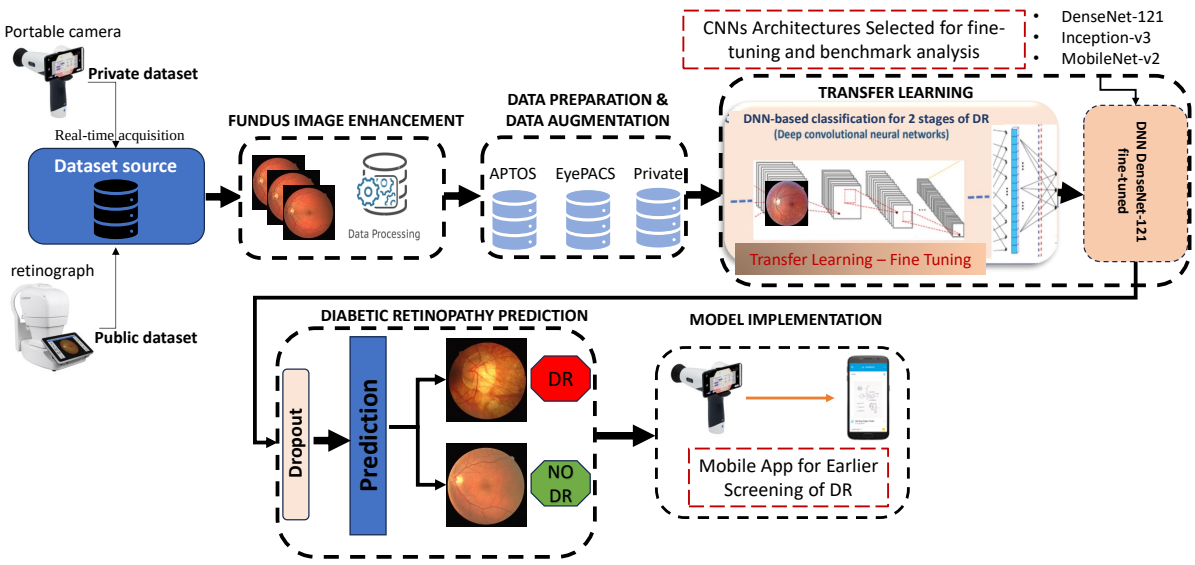

Figure 6: Flowchart of a Deep Learning-Based Mobile App for Early Screening of Diabetic Retinopathy Using Real-Time Handheld Fundus Imaging and Validation with Public Datasets.

The pre-trained architectures were selected specifically to optimize the detection of the two stages of diabetic retinopathy, "NO DR" or "DR", by highlighting specific features extracted at different levels and taking into account the particular structure of the lesions characterizing DR. To achieve this, DenseNet-121, known for its dense structure, enables efficient communication between the different layers of the network. This architecture fa-

cilitates the extraction of fine and complex features present in retinal images, highlighting the subtle details of lesions characteristic of DR, such as microaneurysms, exudates, and hemorrhages. The case is similar for Inception-v3, which features an Inception module that facilitates feature extraction at different spatial scales. This capability is particularly useful for capturing the complex structures of DR lesions, highlighting blood vessel deformations, areas of vascular ischemia, and other characteristic alterations observed in images of the retina affected by the disease. On the other hand, MobileNet-v2, which is designed to maintain high performance while being adapted to the constraints of mobile devices, excels in extracting relevant features with a lightweight architecture. This capability is crucial for highlighting the distinctive features of retinal lesions while ensuring efficient execution on mobile platforms and facilitating the detection of DR stages.

4.1. Data preparation and training

For the three datasets used in DR detection, each dataset was divided into two subgroups: "NO DR" and "DR." The "NO DR" subgroup consists of images without any signs of diabetic retinopathy, while the "DR" subgroup includes images from all four stages of DR severity (1, 2, 3, and 4). This categorization facilitates the distinction between images without retinopathy and those exhibiting varying levels of severity, thereby enabling effective analysis and classification of DR cases. To address challenges related to poor image quality and anomalies in public datasets, certain images containing artifacts were excluded from the APTOS and EyePACS datasets. This exclusion was necessary due to saturation problems, which could negatively impact system performance. The objective of this process was to ensure that only high-quality images were retained for further analysis.

4.2. Data Augmentation and Data splitting

In the preprocessing step, the image resizing was performed to adjust the image size from the preprocessed 255×255 pixels to the required dimensions of 224x224 pixels, ensuring compatibility with the DNN model's input. Subsequently, a variety of data augmentation techniques were applied to enrich the dataset. These techniques encompassed vertical and horizontal flipping, rotation at various angles, and adjustments to brightness and color settings. However, the implementation of data augmentation has been seen as a balanced factor at each stage to mitigate the imbalance between the "NO DR" and "DR" classes. By incorporating these augmentation techniques and ensuring that a balance is maintained between the "DR" class and the "NO DR" class, we aim to enrich the training data by introducing more diversity and variability. This step aims to enhance the model's ability to generalize effectively and capture the wide range of possible scenarios, thus improving its robustness and its ability to handle different cases accurately. Table 3 outlines the distribution and number of images selected for each dataset, along with the count of images before and after data augmentation.

Several studies have employed various proportions to divide datasets into training, validation, and test sets. The allocation of data into different subsets, namely training, validation, and testing sets, holds significant importance in optimizing the learning process and assessing model performance and generalization capabilities. In this context, the distribution of data emphasizes allocating a larger portion to the training set, which

facilitates more effective learning by exposing the model to a diverse range of examples. This distribution strategy strikes a balance between maximizing the training data available to the model for effective learning and guaranteeing sufficient data for rigorous evaluation of performance and generalization potential. A common approach allocates 80% of the data for training, 10% for validation, and the remaining 10% for testing [40]. Alternatively, some studies have chosen to assign 75% of the data for training, with the remaining portion divided between validation and testing [35]. In the specific case under consideration, a distribution of 75% for training, 15% for validation, and 10% for testing has been selected across all three datasets based on the number of images in each dataset. The images for the private dataset of 7200 images were allocated as follows: 5400 images for training, 1080 images for validation, and 720 images for testing. For the APTOS dataset of 9566 images, 7174 images were selected for training, 1433 for validation, and 959 for testing. Finally, for the EyePACS dataset containing 20,000 images, a similar distribution was applied: 15,000 images were assigned to training, 3,000 to validation, and 2,000 to testing.

Table 3: Dataset distribution before and after data augmentation

Datasets	Before data augmentation		After data augmentation
	initial Dataset	Selected Images	Used Images
Private	1321	1321	7200
APTOS	3662	2880	9566
EyePACS	35126	4290	20000

4.3. Designing DNN model for earlier screening of DR

To develop a Deep Neural Network (DNN) model for the binary detection of DR, an approach employing transfer learning with three unique architectures is incorporated as a separated bloc in the proposed flowchart (Fig **6**): DenseNet-121 [41], Inception-v3 [42], and MobileNetV2 [43]. The primary objective of this study is to accurately classify two stages of DR: the presence or absence of DR. Through transfer learning with these three architectures, the extensive knowledge and insights gained from large-scale image datasets are leveraged. This approach significantly enhances the ability to differentiate the early stages of DR, particularly the presence of DR for a subsequent initial examination, by effectively leveraging the valuable information encapsulated in pre-trained models.

The developed architectures undergo training for 200 epochs using the RMSProp (Root Mean Square Propagation) optimization algorithm and the Binary Cross-Entropy (BCE) loss function. The choice of RMSProp as the optimization algorithm and BCE as the loss function is justified by their effectiveness in training the developed architectures over 200 epochs. The learning rate is set to 0.001, and a fixed batch size of 64 is used for training and 32 for validation. In addition, we used the 'sigmoid' activation function in the final layer of the DNN model. This function is commonly employed in binary classification tasks as it produces output from 0 to 1, which is suitable for our classification problem. However, to mitigate the risk of overfitting, the early stopping technique is incorporated, where training is halted after 50 epochs if there is no improvement in validation accuracy. Furthermore, a dropout layer is introduced to the model to address overfitting concerns further. The validation accuracy is evaluated at each epoch, and the model with the

highest validation accuracy is saved using the model checkpoint functionality of the Keras callback mechanism.

4.4. Performance results and discussion

4.4.1. Implementation Framework

The outlined experimentation in this study was conducted on a computer system featuring an NVIDIA Corporation GP102GL [Quadro P6000]. The computer was equipped with an Intel (R) Xeon(R) Gold 6240R, 20 core with 2,40 GHz, and boasted a substantial RAM capacity of 377 GB. The implementation of the models was performed using various software packages, including Python 3.10.9, and deep learning libraries such as Keras with 3.10.9, Keras avec Tensorflow, OpenCV, and Scikit-Learn were utilized in conjunction with the aforementioned libraries for the experimentations.

4.4.2. Evaluation Metrics

Performance evaluations rely on five commonly used metrics, namely, accuracy, sensitivity, specificity, precision, and F1-score, as shown in equations (5), (6), (7), (8), and (9), respectively. These metrics provide insights into different aspects of the classification model's performance.

$$\text{Accuracy} = \frac{\text{TP} + \text{TN}}{\text{TP} + \text{FP} + \text{TN} + \text{FN}} \tag{5}$$

$$\text{Sensitivity} = \frac{\text{TP}}{\text{TP} + \text{FN}} \tag{6}$$

$$\text{Specificity} = \frac{\text{TN}}{\text{TN} + \text{FP}} \tag{7}$$

$$\text{Precision} = \frac{TP}{\text{TP} + FP} \tag{8}$$

$$\text{F1} - \text{Score} = 2 \times \frac{\text{Precision} \times \text{sensitivity}}{\text{Precision} + \text{sensitivity}} \tag{9}$$

4.5. Results and discussion

Fine-tuning includes adapting a pre-trained model to detect the early stages of diabetic retinopathy by fine-tuning its weights on a smaller, task-specific dataset. This approach leverages a model initially trained on a general task and specializes in recognizing the unique features associated with DR detection. Fine-tuning not only improves the model's ability to generalize but also reduces the need for large amounts of labeled data, making it particularly effective in medical imaging where annotated datasets can be limited.

The classification results were evaluated using the datasets described in Section 3.1.3 to assess the performance of the proposed system. As summarized in Table 4, the performance metrics of the three deep learning architectures—DenseNet-121, Inception-v3, and MobileNetV2—demonstrate the superiority of DenseNet-121 across all datasets.

Table 4: Comparative Analysis of Performance Metrics for Three Architectures on Private, APTOS, and EyePACS Datasets

Dataset	Test Prediction Eval. Metrics	Archtectures DenseNet-12	MobileNetv2	Inception-v3
Private	Acc	**98.61**	96.11	96.52
	Sen	**98.33**	94.72	94.72
	Spe	**100.00**	99.72	99.72
	Pre	**98.88**	98.27	98.27
	F1-score	**70.03**	66.97	66.97
APTOS	Acc	**98.03**	97.49	97.38
	Sens	**97.76**	96.42	97.09
	Spe	**99.78**	100.00	100.00
	Pre	**98.20**	98.40	97.53
	F1-score	**67.98**	70.21	65.78
EyesPACS	Acc	**90.90**	87.85	89.14
	Sens	**93.90**	85.30	88.10
	Spe	**99.40**	98.90	98.90
	Pre	**88.58**	89.88	89.89
	F1-score	**69.37**	70.00	68.37

DenseNet-121 achieved an impressive accuracy of 98.61%, sensitivity of 98.33%, specificity of 100.00%, precision of 98.88%, and an F1-score of 70.03%. The results obtained on the APTOS and EyePACS datasets are particularly impressive, where DenseNet-121 achieved accuracy rates of 97.38% and 90.90%, respectively. These findings confirm the effectiveness of DenseNet-121 in accurately detecting DR, showing its capacity to generalize well across diverse datasets, even when faced with variations in data quality and patient demographics.

Further analysis, presented in Table 5, compares the training and validation accuracy for each deep learning architecture across the three datasets. DenseNet-121 consistently outperforms the other models, including Inception-v3 and MobileNetV2, demonstrating its robustness in handling both training and validation phases. This architecture's superior performance can be attributed to its dense connectivity mechanism, which enhances feature propagation and reusability, allowing the model to learn more complex patterns and achieve more accurate predictions. The consistent improvement in performance across all stages further reinforces the reliability of DenseNet-121 for complex classification tasks.

Our findings indicate that DenseNet-121's impressive performance can be harnessed not only for advanced medical diagnostics but also for mobile applications, where efficiency and real-time processing are essential. This is especially significant in teleophthalmology, as deploying such models on mobile devices could facilitate swift and accessible DR screening. Although models like Inception-v3 and MobileNetV2 are also popular in the field, the trade-off between model accuracy and resource utilization, such as inference time and memory usage, must be carefully considered for mobile deployment. DenseNet-121's ability to provide high accuracy while being adaptable for real-time processing on mobile devices positions it as a leading candidate for integration into telemedicine solutions, ultimately improving early detection and patient outcomes in resource-limited settings. Furthermore, Figure 7 visually depicts the accuracy and loss during the training

Table 5: Training and Validation Results Comparison of the Three Architectures

Dataset	DenseNet-121		MobileNet2		Inception-v3	
	Training	Validation	Training	Validation	Training	Validation
Private	**99.81**	**99.37**	99.07	98.12	98.88	98.42
APTOS	**98.91**	**98.81**	98.68	98.51	98.61	98.60
EyePACS	**94.06**	**93.92**	94.54	92.16	91.30	91.43

and validation stages of the DR grading for the Private, APTOS, and EyePACS datasets. The consistently high accuracy and decreasing loss observed in the training and validation curves further validate the robustness and generalization capabilities of DenseNet-121.

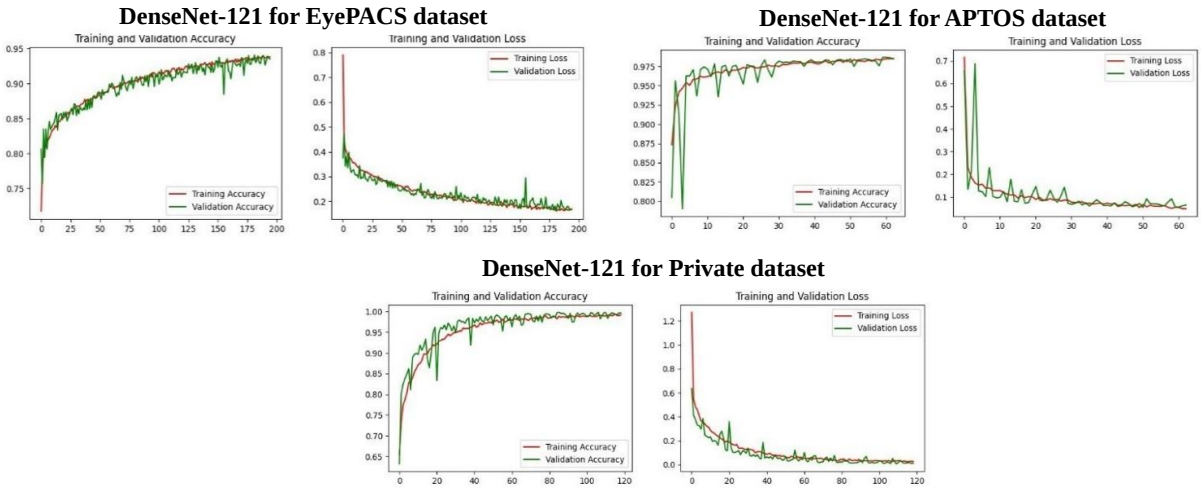

Figure 7: Accuracy and Loss in Training and validation for DenseNet-121 architecture on (a) private dataset (b) APTOS dataset and (c) EyePACS dataset.

The confusion matrix is a valuable tool that provides crucial insights into the performance of a model, enabling the evaluation of its accuracy in classifying instances of DR and No DR. The assessment of classification results for the DR and No DR categories was conducted across three distinct datasets using the confusion matrix. However, Table 6 illustrates the confusion matrix for each dataset, highlighting the consistently superior performance of the DenseNet-121 architecture. Considering these findings, DenseNet-121 has been selected as the optimal architecture due to its exceptional predictive capabilities.

Table 6: Confusion matrix of DenseNet-121 architecture on the Private, APTOS, and EyePACS dataset

		DenseNet-121 Prediction					
		Predicted values					
		Private dataset		APTOS dataset		EyePACS dataset	
		NO DR	DR	NO DR	DR	NO DR	DR
True values	NO DR	**356**	4	**459**	11	**879**	121
	DR	6	**354**	13	**435**	61	**939**

Other performance indices for the transfer learning models are shown in Table 7, which offers a comprehensive overview of the performances of DenseNet-121, MobileNet-v2, and

Table 7: Summary of Performance Indices for Benchmark Analysis: Evaluating Model Complexity and Inference Time

Dataset	Model	Model Depth	Model Complexity	Memory size (MB)	AUROC	Inference time (ms)
Private	DenseNet-121	431	**32.72**	**223.99**	**0.9991**	161.62
	MobileNet-v2	**158**	**34.37**	254.09	0.9974	**118.65**
	Inception-v3	315	48.01	284.02	0.9945	133.50
APTOS	DenseNet-121	431	**32.72**	**223.99**	**0.9958**	210.03
	MobileNet-v2	**158**	**34.37**	254.09	0.9925	**157.93**
	Inception-v3	315	48.01	284.02	0.9919	170.84
EyePACS	DenseNet-121	431	**32.72**	**223.99**	**0.9722**	137.52
	MobileNet-v2	**158**	**34.37**	254.09	0.9534	**104.72**
	Inception-v3	315	48.01	284.02	0.9571	105.54

Inception-v3. Across the three evaluated datasets (Private, APTOS, and EyePACS). DenseNet-121 consistently demonstrates remarkable performance with high AUROC values for each dataset. For example, on the Private dataset, DenseNet-121 achieves an impressive AUROC of 0.9991, whereas MobileNet-v2 and Inception-v3 exhibit competitive but slower AUROC values of 0.9974 and 0.9945, respectively. These values highlight the efficacy of the models in accurately classifying the datasets. Furthermore, the reported inference times, such as 161.62 ms for DenseNet-121 on the Private dataset, provide insights into the computational efficiency of the models.

Figure 8 visualizes the AUROC values obtained by DenseNet-121, MobileNet-v2, and Inception-v3 across different datasets. DenseNet-121 consistently achieves the highest AUROC values, demonstrating its superior performance in classification tasks compared to the other models. Although MobileNet-v2 and Inception-v3 exhibit slightly lower AUROC values, they still showcase competitive performance. These findings provide a comprehensive understanding of the performance and efficiency trade-offs among the evaluated models. DenseNet-121 stands out as the top performer in terms of AUROC values, indicating its effectiveness in classification tasks. On the other hand, MobileNet-v2 and Inception-v3 offer computational advantages in terms of faster inference times due to their lighter and less complex architectures. These insights are crucial for selecting the most appropriate transfer learning model based on the specific requirements of the application at hand.

The researchers explored different transfer learning models in the field of DR detection [12]-[18]. In the end, Table 8 presents a detailed comparison of our approach with the state of the art (SOTA), highlighting our ability to improve the quality of retinal images captured by mobile devices or fundus retinography. This improvement in image quality is essential for accurate detection of DR, offering the potential to prevent blindness, particularly in older patients.

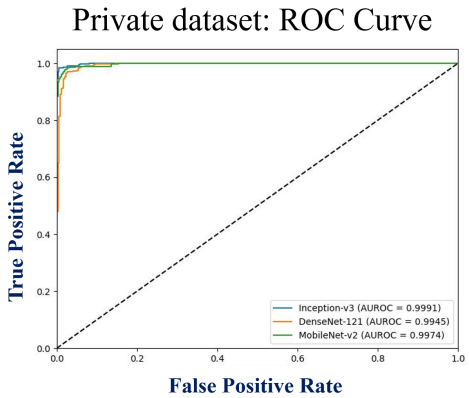

(a)

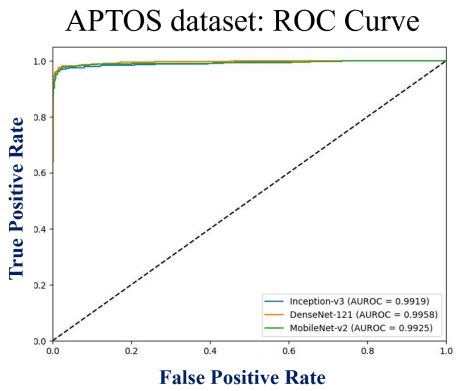

(b)

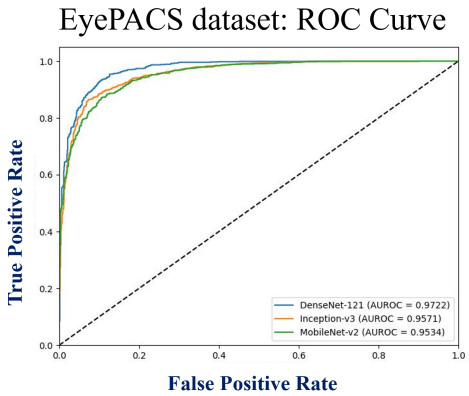

(c)

Figure 8: ROC curves obtained from models fitted to the Private (a), APTOS (b), and EyePACS (c) datasets.

Table 8: A comparison with state-of-the-art methods.

Works	**Technique**	**Dataset**	**Performance metrics**
Gulshan et al. [12]	CNNs	EyePACS	Sen=90.3% , Spe=98.1%
Wang et al. [13]	TL AlexNet, VGG-16 and InceptionNetV3	EyePACS	Acc = 37.43%, 50.03%, 63.23%
Pamadi et al. [14]	TL MobileNetV2	APTOS	Acc = 78%
Zhou et al. [15]	Multi-Task learning	EyePACS	Acc = 63.22%
Deepa et al. [16]	Ensemble method (InceptionV3, Xception)	EyePACS	Acc = 96.2% for Ensemble method, Acc = 85.4%for InceptionV3
Qureshi et al. [17]	Active Deep Learning (ADL)	EyePACS	Acc = 95.10%, Sen=92.20%, Sep= 95.10%
Our approach	**Fine-tunned DenseNet-121**	**Private, EyePACS and APTOS**	**Acc = 98.61%, 98.03%, 90.90%; Sen = 98.33%, 97.76%, 93.90%; Sep = 100.00%, 99.78%, 99.40%**

4.6. Real-time Mobile App-based Tele Ophtalmology

The development and deployment of a real-time diagnostic system for DR include several stages. Firstly, retinal images are captured in real-time using an oDocs nun IR handheld fundus camera. Next, the retinal images are enhanced using the specified algorithms. Then, a DR prediction DenseNet-121 model is adapted and fine-tuned to accurately identify the presence or absence of DR pathology. The DenseNet-121 model was adapted and fine-tuned, selected from several alternative models. Then, it is deployed on mobile smartphone applications. This accessibility enables specialist ophthalmologists to use the mobile App effectively to classify and diagnose DR. Diagnostic results are transmitted in real time to a pilot site affiliated with the Faculty of Medicine at the HASSAN II Hospital in Fez, enabling centralized monitoring and regular assessment. This integrated system provides crucial clinical support and improves medical decision-making, enabling early detection and more effective management of DR. Figure 9 presents the protocol of earlier screening of DR in remote medical centers or areas with limited access to ophthalmologists.

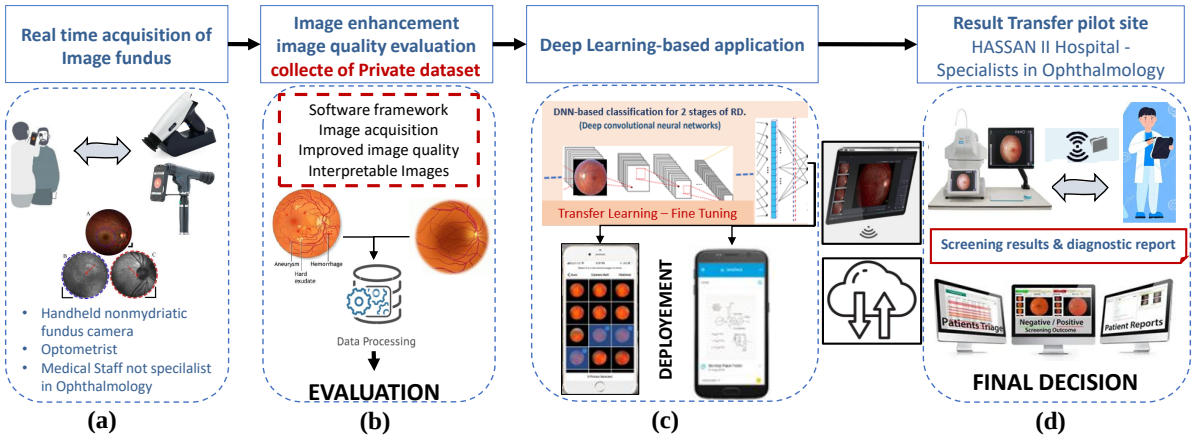

Figure 9: The Early DR Screening in Remote Medical Centers or Resource-Limited Areas: A Comprehensive Workflow from Real-Time Acquisition (a), Image Enhancement (b), Deep Learning Model Application (c), to Screening & transfer result (d).

The DenseNet-121 model, recognized for its strong performance, is integrated into a mobile application offering a practical and portable solution. A comprehensive planning process was employed to delineate the application's objectives, analyze the distinct requirements of end-users—particularly healthcare practitioners operating in clinical settings such as medical caravans—and establish the core functional specifications. The technical implementation leverages modern technologies, including JavaScript as the programming language, to ensure smooth and efficient integration of the DenseNet-121 model. The application facilitates optimized image processing and accurate automated diagnosis. This interface is designed to minimize user effort, making interactions more efficient in time-sensitive, resource-constrained settings. Key features like real-time image acquisition, enhanced image quality using advanced techniques, and user-friendly result visualization have been integrated. Rigorous testing has assessed the application's robustness, data security, and overall performance in real-world conditions.

Figure 10 provides a detailed description of the deployment steps for the DenseNet-121 optimized and fine-tuned model on a mobile app as an initial prototype. The conversion of the model to a *.tflite* format is facilitated using the TensorFlow Lite interpreter. Subsequently, the *.tflite* model is deployed on smartphones using the Java programming language within the Android Studio Integrated Development Environment (IDE). Several libraries, including TensorFlow, Keras, and OpenCV, are utilized during the implementation to ensure efficient image processing and smooth execution of the model. The successful deployment of the model on smartphones offers a practical and effective solution for the early detection of DR.

The implementation on smartphones provides several advantages, notably the high portability and accessibility of screening, which eliminates the need for specialized equipment. These features are particularly beneficial in settings where medical resources are scarce, such as rural areas or during medical caravans. Additionally, extending the solution to other platforms, such as desktops and tablets, further enhances its versatility and overall impact. Figure 11 demonstrates the successful deployment of the model on an Android smartphone, showcasing the system's ability to deliver real-time, accurate results. Moreover, our vision extends beyond DR detection. Once the system is established and validated for DR diagnosis, the goal is to generalize the model and broaden its scope to detect other ocular pathologies, such as glaucoma, age-related macular degeneration (AMD), and more. This expansion will include training the model on diverse datasets specific to each pathology, ultimately empowering clinicians to use the application as a versatile tool for diagnosing a wide range of ocular conditions.

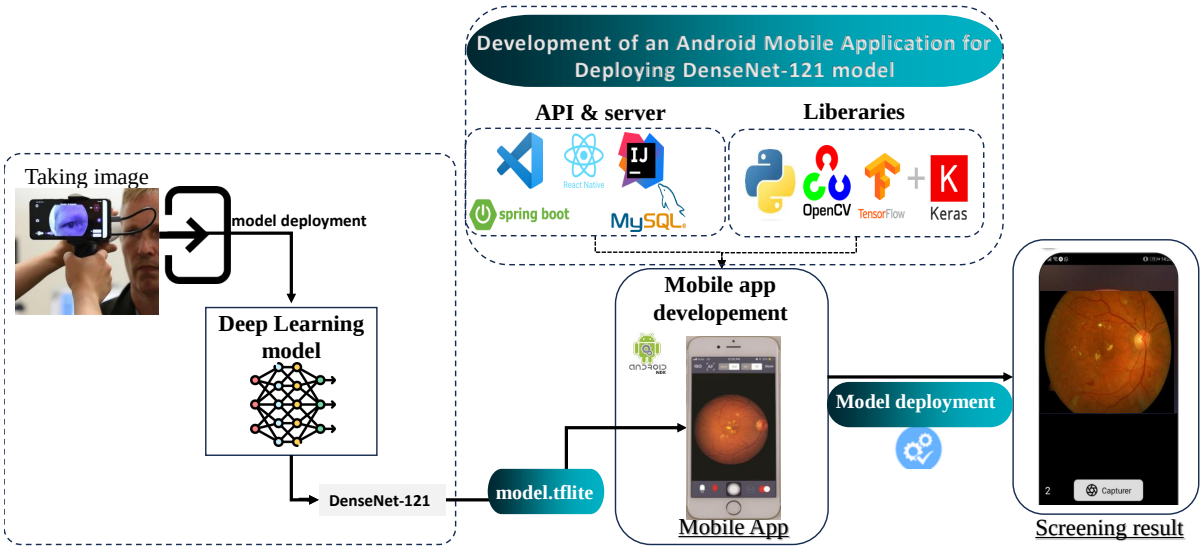

Figure 10: The Workflow for Implementation on Smartphone, Desktop, and Tablet Platforms

In addition, the combination of two publicly available datasets, APTOS and EyePACS, with our private dataset has validated the results obtained. The integration of multiple diverse datasets reduces the risk of bias that may result from dependence on a single data source. The APTOS and EyePACS datasets contribute valuable variability, encompassing a broad spectrum of patient demographics, imaging conditions, and resolution

qualities, thereby enhancing the model's generalizability. Moreover, by incorporating our private dataset, we introduce real-world data specific to the population at CHU Hassan II, ensuring that the model is better suited for deployment in clinical settings with similar demographic characteristics. This diversified approach ultimately strengthens the robustness and reliability of the model, enabling it to perform effectively across various scenarios and environments and supporting its use for real-time, early screening in mobile applications.

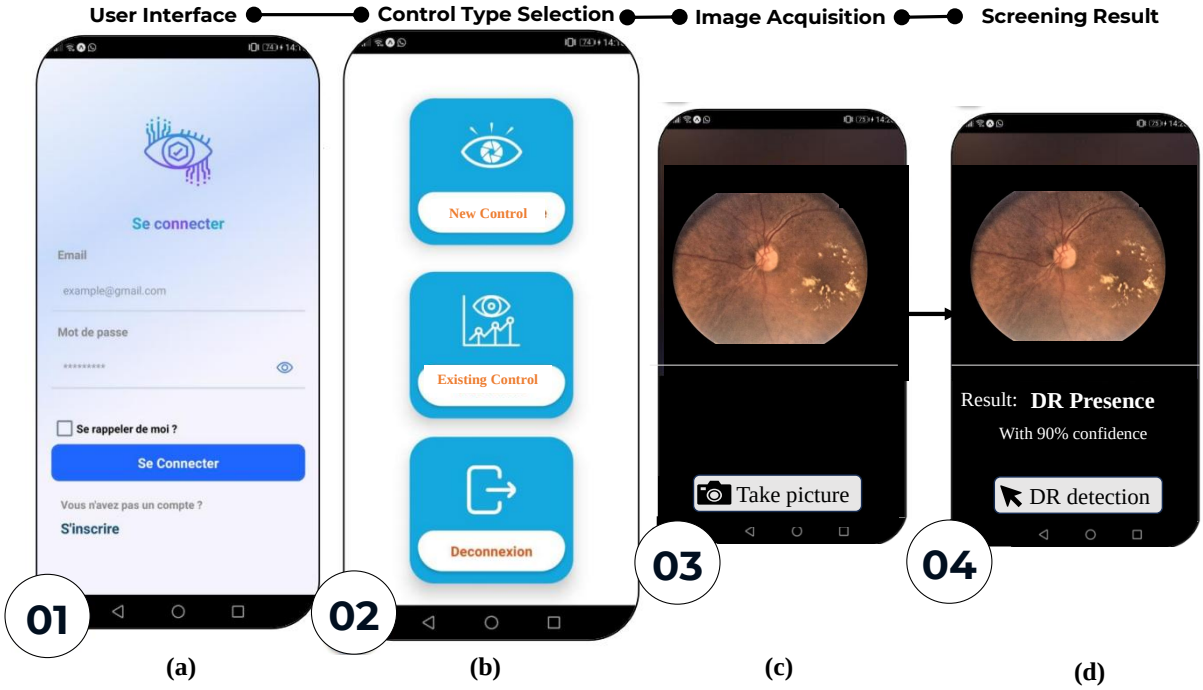

Figure 11: Demonstration of Smartphone Graphical Interface for DR Detection: User Interface for Connection (a), Control Type Selection (b), Image Acquisition (c), and Screening Result Display.

5. CONCLUSIONS AND FUTURE WORKS

In this paper, we propose the development of a deep convolutional neural network (DCNN) based on fine-tuning and transfer learning for the early detection of DR. Our approach, which leverages the optimized and fine-tuned DenseNet-121 model, achieved high performance on publicly available datasets (APTOS and EyePACS) and a our private dataset, demonstrating an accuracy of 98.61% on the private dataset, 98.03% on APTOS, and 90.90% on EyePACS. The DenseNet-121 model was notably efficient regarding complexity and memory usage, with 161.62 ms in inference times, which is suitable for real-time mobile applications. These results highlight the potential of DCNN models for accurate and efficient early screening of DR. Additionally, we developed a mobile application using a handheld fundus camera to integrate the DenseNet-121 model for real-time DR screening. This mobile solution allows for early detection in underserved regions, where access to ophthalmologists and specialized equipment is limited. By focusing on mobile deployment, we provide a practical, accessible, and cost-effective approach to DR detection, contributing to improved clinical outcomes in remote settings. As future work, our objective is to enhance the efficiency of the models by reducing inference time and

deploying them on tablets and desktops. We aim to compare the performance of the models on these three platforms, achieving real-time diagnosis with reduced processing time while minimizing system resource consumption. Then, a field validation campaign will be conducted in the Fez region to assess the system's effectiveness in real-world clinical environments.

Acknowledgements

We would like to express our sincere gratitude to the Gaspard Monge Computer Science Laboratory at ESIEE-Paris, Gustave Eiffel University, France, as well as the Ministry of Higher Education of Morocco for their support of the bilateral program and to SIMAD-PR, N° 48672RG.

Declaration of competing interest

The authors declare that there are no conflicts of interest regarding the publication of this paper.

Data availability

APTOS dataset is available at www.kaggle.com/competitions/aptos2019-blindness-detection.
EyePACS dataset is available at www.kaggle.com/competitions/diabetic-retinopathy-detection/data.
The private dataset is not available for public access.

References

[1] «Vision impairment and blindness», https://www.who.int/news-room/fact-sheets/detail/blindness-and-visual-impairment.

[2] T. Zl et al., "Global Prevalence of Diabetic Retinopathy and Projection of Burden through 2045: Systematic Review and Meta-analysis," Ophthalmology, vol. 128, no. 11, Nov. 2021,https://doi.org/10.1016/j.ophtha.2021.04.027.

[3] M.J.Burton et al., «The Lancet Global Health Commission on Global Eye Health: vision beyond 2020 », Lancet Glob. Health, vol. 9, no 4, p. e489-e551, avr. 2021, https://doi.org/10.1016/S2214-109X(20)30488-5.

[4] T. Begum et al., "Diagnostic Accuracy of Detecting Diabetic Retinopathy by Using Digital Fundus Photographs in the Peripheral Health Facilities of Bangladesh: Validation Study," JMIR Public Health and Surveillance, vol. 7, no. 3, p. e23538, Mar. 2021, https://doi.org/10.2196/23538.

[5] A. R. Elam, V. L. Tseng, T. M. Rodriguez, E. V. Mike, A. K. Warren, and A. L. Coleman, "DISPARITIES IN VISION HEALTH AND EYE CARE," Ophthalmology, vol. 129, no. 10, pp. e89–e113, Oct. 2022, https://doi.org/10.1016/j.ophtha.2022.07.010.

[6] D. An, B. Tan, D.-Y. Yu, and C. Balaratnasingam, "Differentiating Microaneurysm Pathophysiology in Diabetic Retinopathy Through Objective Analysis of Capillary Nonperfusion, Inflammation, and Pericytes," Diabetes, vol. 71, no. 4, pp. 733–746, Apr. 2022, https://doi.org/10.2337/db21-0737.

[7] L. Walsh, S. C. Hong, R. J. Chalakkal, and K. C. Ogbuehi, "A Systematic Review of Current Teleophthalmology Services in New Zealand Compared to the Four Comparable Countries of the United Kingdom, Australia, United States of America (USA) and Canada," Clinical Ophthalmology, vol. 15, pp. 4015–4027, Oct. 2021, https://doi.org/10.2147/OPTH.S294428.

[8] H. El Alami et al., "Prevalence and risk factors of chronic complications among patients with type 2 diabetes mellitus in Morocco: a cross-sectional study," Pan Afr Med J, vol. 41, p. 182, Mar. 2022, https://doi.org/10.11604/pamj.2022.41.182.25532.

[9] "Journal de la Société Marocaine d'Ophtalmologie.", https://revues.imist.ma/index.php/jsmo.

[10] G. Labiris, E.-K. Panagiotopoulou, and V. P. Kozobolis, "A systematic review of teleophthalmological studies in Europe," Int J Ophthalmol, vol. 11, no. 2, pp. 314–325, Feb. 2018, https://doi.org/10.18240/ijo.2018.02.22.

[11] G. Quellec et al., "Automatic detection of referral patients due to retinal pathologies through data mining," Medical Image Analysis, vol. 29, pp. 47–64, Apr. 2016, https://doi.org/10.1016/j.media.2015.12.006.

[12] V. Gulshan et al., "Development and Validation of a Deep Learning Algorithm for Detection of Diabetic Retinopathy in Retinal Fundus Photographs," JAMA, vol. 316, no. 22, p. 2402, Dec. 2016, https://doi.org/10.1001/jama.2016.17216

[13] X. Wang, Y. Lu, Y. Wang, and W.-B. Chen, "Diabetic Retinopathy Stage Classification Using Convolutional Neural Networks," in 2018 IEEE International Conference on Information Reuse and Integration (IRI), Jul. 2018, pp. 465–471. https://doi.org/10.1109/IRI.2018.00074.

[14] A. M. Pamadi, A. Ravishankar, P. Anu Nithya, G. Jahnavi, and S. Kathavate, "Diabetic Retinopathy Detection using MobileNetV2 Architecture," in 2022 International Conference on Smart Technologies and Systems for Next Generation Computing (ICSTSN), Villupuram, India: IEEE, Mar. 2022, pp. 1–5. https://doi.org/10.1109/ICSTSN53084.2022.9761289.

[15] K. Zhou et al., "Multi-Cell Multi-Task Convolutional Neural Networks for Diabetic Retinopathy Grading," in 2018 40th Annual International Conference of the IEEE Engineering in Medicine and Biology Society (EMBC), Jul. 2018, pp. 2724–2727. https://doi.org/10.1109/EMBC.2018.8512828.

[16] V. Deepa, C. S. Kumar, and T. Cherian, "Ensemble of multi-stage deep convolutional neural networks for automated grading of diabetic retinopathy using image patches," Journal of King Saud University - Computer and Information Sciences, vol. 34, no. 8, Part B, pp. 6255–6265, Sep. 2022,https://doi.org/10.1016/j.jksuci.2021.05.009.

[17] I. Qureshi, J. Ma, and Q. Abbas, "Diabetic retinopathy detection and stage classification in eye fundus images using active deep learning," Multimed Tools Appl, vol. 80, no. 8, pp. 11691–11721, Mar. 2021, https://doi.org/10.1007/s11042-020-10238-4

[18] N. Abou Baker, N. Zengeler, and U. Handmann, "A Transfer Learning Evaluation of Deep Neural Networks for Image Classification," Machine Learning and Knowledge Extraction, vol. 4, pp. 22–41, Jan. 2022, https://doi.org/10.3390/make4010002.

[19] N. Tsiknakis et al., "Deep learning for diabetic retinopathy detection and classifi-

cation based on fundus images: A review," Computers in Biology and Medicine, vol. 135, p. 104599, Aug. 2021, https://doi.org/10.1016/j.compbiomed.2021.104599.

[20] E. K. Chin, B. V. Ventura, K.-Y. See, J. Seibles, and S. S. Park, "Nonmydriatic Fundus Photography for Teleophthalmology Diabetic Retinopathy Screening in Rural and Urban Clinics," Telemed J E Health, vol. 20, no. 2, pp. 102–108, Feb. 2014, https://doi.org/10.1089/tmj.2013.0042.

[21] S. Iqbal, T. M. Khan, K. Naveed, S. S. Naqvi, and S. J. Nawaz, "Recent trends and advances in fundus image analysis: A review," Computers in Biology and Medicine, vol. 151, p. 106277, Dec. 2022, https://doi.org/10.1016/j.compbiomed.2022.106277.

[22] M. E. Ryan et al., "Comparison Among Methods of Retinopathy Assessment (CAMRA) Study," Ophthalmology, vol. 122, no. 10, pp. 2038–2043, Oct. 2015, https://doi.org/10.1016/j.ophtha.2015.06.011.

[23] R. Rajalakshmi et al., "Validation of Smartphone Based Retinal Photography for Diabetic Retinopathy Screening," PLoS One, vol. 10, no. 9, p. e0138285, Sep. 2015, https://doi.org/10.1371/journal.pone.0138285.

[24] E. Midena et al., "Handheld Fundus Camera for Diabetic Retinopathy Screening: A Comparison Study with Table-Top Fundus Camera in Real-Life Setting," J Clin Med, vol. 11, no. 9, p. 2352, Apr. 2022, https://doi.org/10.3390/jcm11092352.

[25] L. Lu et al., "Diagnostic accuracy of handheld fundus photography: A comparative study of three commercially available cameras," PLOS Digital Health, vol. 1, no. 11, p. e0000131, Nov. 2022, https://doi.org/10.1371/journal.pdig.0000131.

[26] T. W. Rogers et al., "Evaluation of an AI system for the detection of diabetic retinopathy from images captured with a handheld portable fundus camera: the MAILOR AI study," Eye, vol. 35, no. 2, Art. no. 2, Feb. 2021, https://doi.org/10.1038/s41433-020-0927-8.

[27] C. Khodris, B. Ahmed, C. Fouad, A. Meriem, B. A. Idriss, and H. Tairi, "Artificial intelligence in ophthalmology: the ophthalmologist's opinion," in 2020 International Conference on Intelligent Systems and Computer Vision (ISCV), Fez, Morocco: IEEE, Jun. 2020, pp. 1–5. https://doi.org/10.1109/ISCV49265.2020.9204195.

[28] M. Hassan, B. Ahmed, C. Fouad, A. Meriem, A. Benatiya, and B. M. Faouzi, "Ganglion Cell Layer Analysis in Nonarteritic Anterior Ischemic Optic Neuropathy in Diabetic Patients: From the Acute to Resolving Phases," Journal of Research in Medical and Dental Science, vol. 9, no. 11, 2021 https://www.jrmds.in/

[29] S. B. Sayadia, Y. Elloumi, R. Kachouri, M. Akil, A. B. Abdallah, and M. H. Bedoui, "Automated method for real-time AMD screening of fundus images dedicated for mobile devices," Med Biol Eng Comput, vol. 60, no. 5, pp. 1449–1479, May 2022, https://doi.org/10.1007/s11517-022-02546-8.

[30] "oDocs nun IR," oDocs Eye Care.https://odocseyecare.shop/products/odocs-nun-ir.

[31] U. K. Acharya and S. Kumar, "Swarm intelligence based adaptive gamma-corrected (SIAGC) retinal image enhancement technique for early detection of diabetic retinopathy," Optik, vol. 247, p. 167904, Dec. 2021, https://doi.org/10.1016/j.ijleo.2021.167904.

[32] "APTOS 2019 Blindness Detection.", https://kaggle.com/competitions/

aptos2019-blindness-detection.
[33] "Papers with Code - Kaggle EyePACS Dataset.", https://paperswithcode.com/dataset/kaggle-eyepacs.
[34] K. C. Jordan, M. Menolotto, N. M. Bolster, I. A. Livingstone, and M. E. Giardini, "A review of feature-based retinal image analysis," Expert Review of Ophthalmology, vol. 12, no. 3, pp. 207–220, May 2017, https://doi.org/10.1080/17469899.2017.1307105.
[35] N. Band et al., "Benchmarking Bayesian Deep Learning on Diabetic Retinopathy Detection Tasks," Nov. 23, 2022, arXiv: arXiv:2211.12717. http://arxiv.org/abs/2211.12717.
[36] A. Mvoulana, R. Kachouri, and M. Akil, "Fully automated method for glaucoma screening using robust optic nerve head detection and unsupervised segmentation based cup-to-disc ratio computation in retinal fundus images," Computerized Medical Imaging and Graphics, vol. 77, p. 101643, Oct. 2019, https://doi.org/10.1016/j.compmedimag.2019.101643.
[37] Computer Engineering, Sriwijaya University, Indralaya, Indonesia and Erwin, "Improving Retinal Image Quality Using the Contrast Stretching, Histogram Equalization, and CLAHE Methods with Median Filters," IJIGSP, vol. 12, no. 2, pp. 30–41, Apr. 2020, https://doi.org/10.5815/ijigsp.2020.02.04.
[38] S. Dash and M. R. Senapati, "Enhancing detection of retinal blood vessels by a combined approach of DWT, Tyler Coye, and Gamma correction," Biomedical Signal Processing and Control, vol. 57, p. 101740, Mar. 2020, https://doi.org/10.1016/j.bspc.2019.101740.
[39] O. Appiah, M. Asante, and J. B. Hayfron-Acquah, "Improved approximated median filter algorithm for real-time computer vision applications," Journal of King Saud University - Computer and Information Sciences, vol. 34, no. 3, pp. 782–792, Mar. 2022, https://doi.org/10.1016/j.jksuci.2020.04.005.
[40] C. Mohanty et al., "Using Deep Learning Architectures for Detection and Classification of Diabetic Retinopathy," Sensors, vol. 23, no. 12, p. 5726, Jun. 2023, https://doi.org/10.3390/s23125726.
[41] G. Huang, Z. Liu, L. van der Maaten, and K. Q. Weinberger, "Densely Connected Convolutional Networks," Jan. 28, 2018, arXiv: arXiv:1608.06993. https://doi.org/10.48550/arXiv.1608.06993.
[42] C. Szegedy, V. Vanhoucke, S. Ioffe, J. Shlens, and Z. Wojna, "Rethinking the Inception Architecture for Computer Vision," in 2016 IEEE Conference on Computer Vision and Pattern Recognition (CVPR), Jun. 2016, pp. 2818–2826. https://doi.org/10.1109/CVPR.2016.308.
[43] M. Sandler, A. Howard, M. Zhu, A. Zhmoginov, and L.-C. Chen, "MobileNetV2: Inverted Residuals and Linear Bottlenecks," Mar. 21, 2019, arXiv: arXiv:1801.04381. https://doi.org/10.48550/arXiv.1801.04381.